

## PARAFFIN OIL TREATMENT IN A GREEN IGUANA WITH PEBBLE OBSTRUCTION

Lora Koenhems<sup>1\*</sup>, Remzi Gönül<sup>1</sup>, Banu DokuzeYLül<sup>1</sup>, M. Erman Or<sup>1</sup>

<sup>1</sup>Department of Internal Medicine, Faculty of Veterinary Medicine, Istanbul University, Istanbul, Turkey

**Abstract.** A 2 years old green iguana with anorexia and lethargy referred to our clinic. Solid masses was palpated within the coelom. Radio-opaque material were seen in laterolateral view. Treatment was instituted with enrofloxacin (10 mg/kg PO, once daily), paraffin oil, and intracoelomic crystalloid fluids. the owner saw pebbles in the gaita. To the authors' knowledge foreign bodies obstruction is rarely reported in iguanas and this is the first case report suggesting the usage of paraffin oil in this cases.

**Keywords:** green iguana, foreign body, obstruction, paraffin oil.

**Corresponding Author:** Lora Koenhems, Department of Internal Medicine, Faculty of Veterinary Medicine, Istanbul University, 34320, Avcılar, Istanbul, Turkey,  
e-mail: [lomekoh@istanbul.edu.tr](mailto:lomekoh@istanbul.edu.tr)

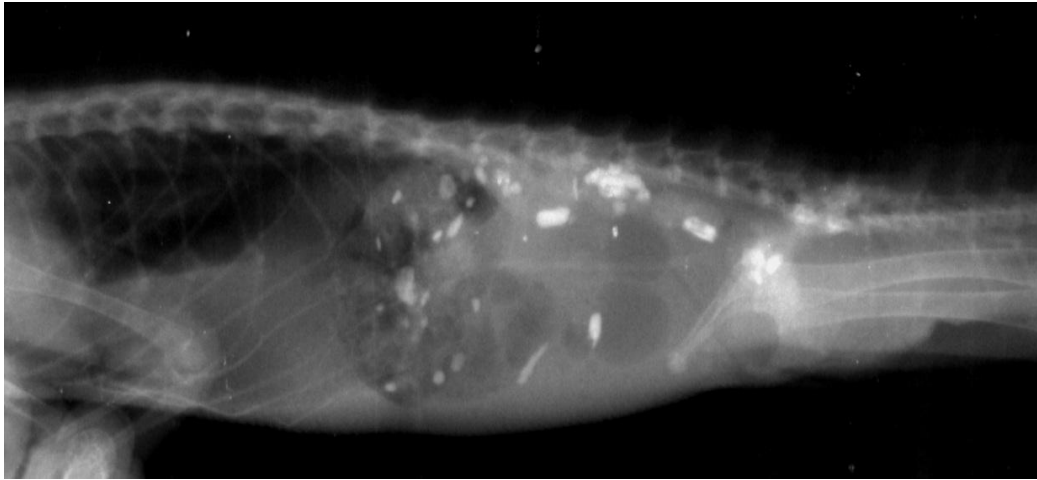
**Manuscript received:** 20 January 2017

### 1. Introduction

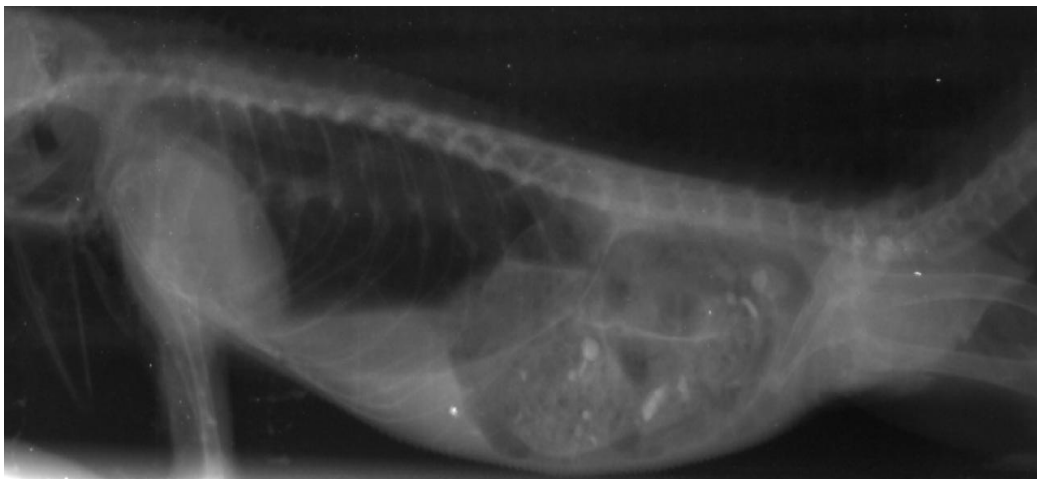
A two year-old male green iguana with loss of appetite and lethargy present more than 2 week was referred to our department. The animal was fed with a specific diet (brand unknown) and fruits; tap water was available at all the time. The iguana was housed in a terrarium of about 1.4x2.4 m<sup>2</sup> floor space and 2.5 m height. The terrarium floor was lined with newspaper and pebbles.

The iguana was depressed and dehydrated on physical examination. Solid masses was palpated within the coelom. The masses were investigated with radiography and radio-opaque materials were seen all over the coelom (Fig.1).

Treatment was instituted with enrofloxacin (10 mg/kg PO, once daily), paraffin oil and intracoelomic crystalloid fluids. Food restriction was applied on the first day of the treatment. On the second day fresh fruits were offered. Tap water was available all the time. The owner was instructed to pay attention to defecation. Two days after the treatment pebbles were seen in the gaita and movements of the pebbles were seen in radiography of the iguana. 5 days later another LL xray was taken and most of the pebbles were gone (Fig. 2). The final diagnosis was made as gastrointestinal foreign body obstruction due to pebbles. The treatment continued for a week. On the follow-up examination after one week the iguana started to eat.



**Figure 1.** Lateral radiography of a green iguana with foreign bodies within coelom



**Figure 2.** Lateral radiography of a green iguana after the treatment

## 2. Discussion

Green iguana (*Iguana iguana*) has been fed more as a pet in recent years. They are herbivorous reptile that native to Central and South America (Büker *et al.* 2010, Mitchell and Diaz-Figueroa 2005). Common gastrointestinal diseases in reptiles are gastritis, intestinal intussusceptions, diarrhea due to parasites and dietary fiber, neoplasms, and foreign bodies. Gastrointestinal foreign bodies reported in reptiles, turtles, crocodiles, caiman, and snakes. Gastrointestinal foreign bodies, caused mostly by ingested food are not uncommon, however to the author's knowledge, reports of foreign bodies in reptiles are very rare (Büker *et al.* 2010). Treatment choice is generally surgical intervention in these cases. Bradley *et al.* (1991) described 2 radiopaque stones, and Büker *et al.* (2010) reported a linear body ingested by a green iguana. These case reports concluded that surgery

is indicated for removal of foreign bodies (Bradley *et al.* 1991, Büker *et al.* 2010). Medical treatment applied to the iguana reported in the present case report. This is also the first case report with concern to paraffin oil usage in the treatment of foreign bodies in the green iguana. Paraffin oil is a transparent, colourless, odourless, or almost odourless, oily liquid composed of saturated hydrocarbons obtained from petroleum. Paraffin oil generally used for constipation cases in human medicine and it appears to work primarily as a stool lubricant (Mitchell and Diaz-Figueroa 2005; Sharif *et al.* 2001).

Reptiles with gastrointestinal foreign bodies may present with acute lethargy and anorexia. Vomiting is a rare clinical sign and usually has a poor prognosis (Benson 1999, Bradley *et al.* 1991). The patient described in the present report showed anorexia and lethargy.

Diagnostic images are an important diagnostic tool in gastro-intestinal diseases. Metal and mineral foreign bodies can be detected using survey radiographs. Gas-distended gastrointestinal tract is the typical evidence of the obstruction (Benson 1999). Foreign material and gas distended gastrointestinal tract were seen on the laterolateral radiographs of the iguana.

The present case demonstrates the risk of foreign body ingestion in iguanas. Foreign bodies obstruction is rarely reported in iguanas. In those rare reports the treatment were surgical but we believe that this cases can be treated with medical treatment. In this case report we wanted to open a new aspect about the treatment of choice in foreign body ingestions. For this reason we used paraffin oil which is used in human medicine frequently. To the authors' knowledge this is the first case report suggesting the usage of paraffin oil in this cases. It can be concluded from this case report that medical management of foreign bodies in the iguana can be effective and afford a good prognosis for recovery.

## References

1. Benson K.G., (1999) Reptilian Gastrointestinal diseases, *Seminars in Avian and exotic pet medicine*, 8(2), 90-97.
2. Bradley T.A., Carpenter J.W., Munana K.R., Douglass J., (1991) Clinical challenge, case 2, *Journal of Zoo and Wildlife Medicine*, 22, 505–506.
3. Büker M., Foldenauer U., Simova-Curd S. Martig S., Hatt J.M., (2010) Gastrointestinal obstruction caused by a radiolucent foreign body in a green iguana (*Iguana Iguana*), *Canadian Veterinary Journal*, 51, 511-514.
4. Mitchell M.A., Diaz-Figueroa O., (2005) Clinical reptile gastroentology, *Veterinary Clinical Exotic Animal*, 8, 277-298.
5. Sharif F., Crushell E., O'Driscoll K., Bourke B., (2001) Liquid paraffin: a reappraisal of its role in the treatment of constipation, *Archives of Disease in Childhood*, 85, 121-124.